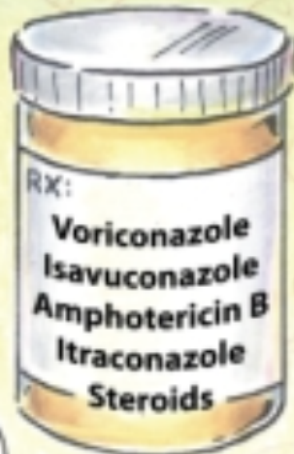


Aspergillosis



Cerebral Aspergillosis

- Ring-Enhancing Lesion

Aspergilloma "Fungus Ball"

- Maxillary Sinus
- Preexisting Pulmonary cavities in Lung Apex

Otomycosis

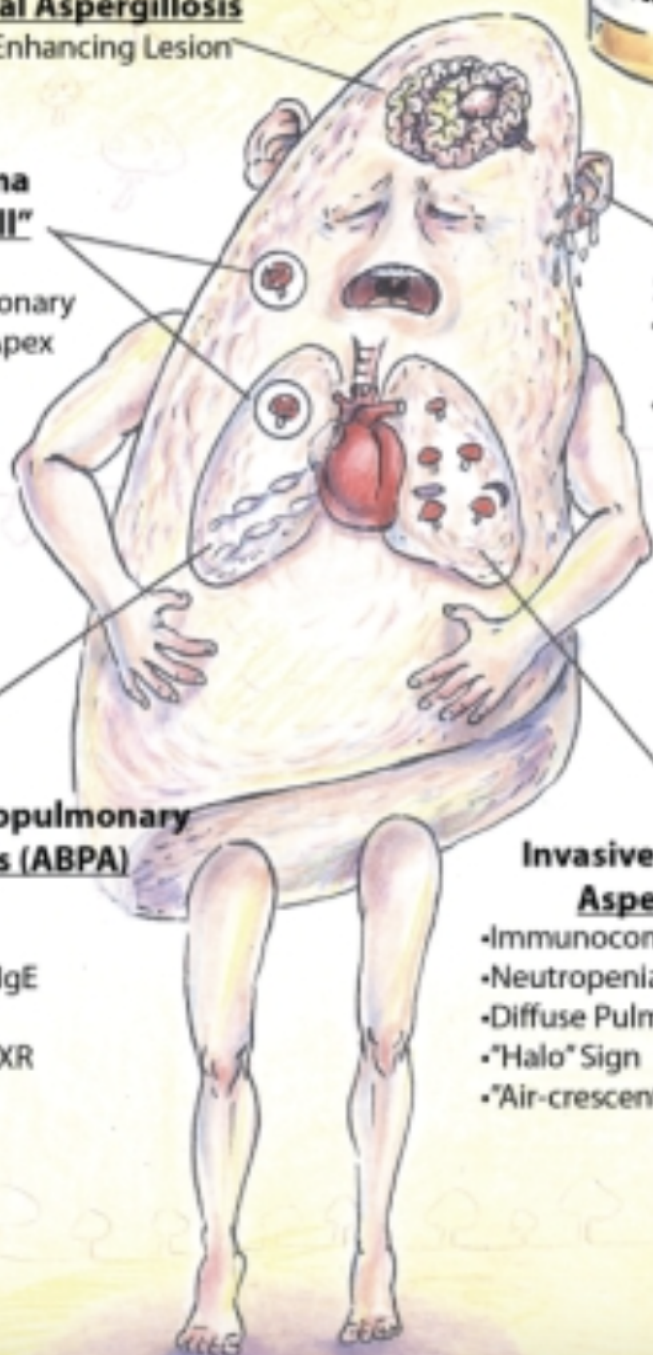
- *A. niger*
Black Drainage
- *A. fumigatus*
Green Drainage

Allergic Bronchopulmonary Aspergillosis (ABPA)

- Asthma or CF
- Bronchiectasis
- ⊕ Skin test / ↑ IgE
- Eosinophilia
- Infiltrates on CXR

Invasive Pulmonary Aspergillosis

- Immunocompromised
- Neutropenia
- Diffuse Pulmonary Infiltrates
- "Halo" Sign
- "Air-crescent" Sign



Blastomycosis

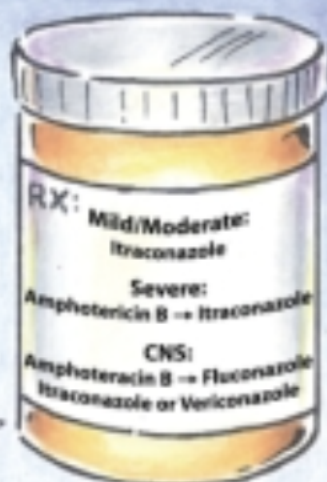
(Gilchrist's Disease)

S	M	T	W	T	F	S
Incubation: 1-3 Months						
Lung & Skin Involvement						
Untreated = High Mortality						
Can Mimic TB or Cancer						
Not Contagious						
Immunocompromised = Worse Infection						


Blastomyces dermatitidis



Dimorphic Fungi



Fatigue



Headache

Meningitis

Inhaled Conidia



Myalgia



Fever

Chills

Cough

Pleuritic Chest Pain

Cavitary Lesion (Rare)

Mediastinal Lymphadenopathy

Nodule/Granuloma

Shortness of Breath

Alveolar or Mass-like Pneumonia (Often Mistaken for Cancer)

GU Involvement

I can catch this too!

Ulcerative Lesions

Verrucous Lesions

Osteomyelitis

Erythema Nodosum

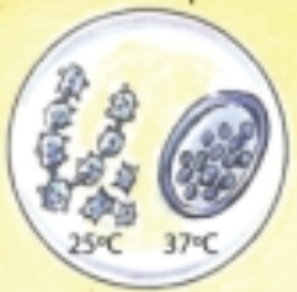


Coccidioidomycosis

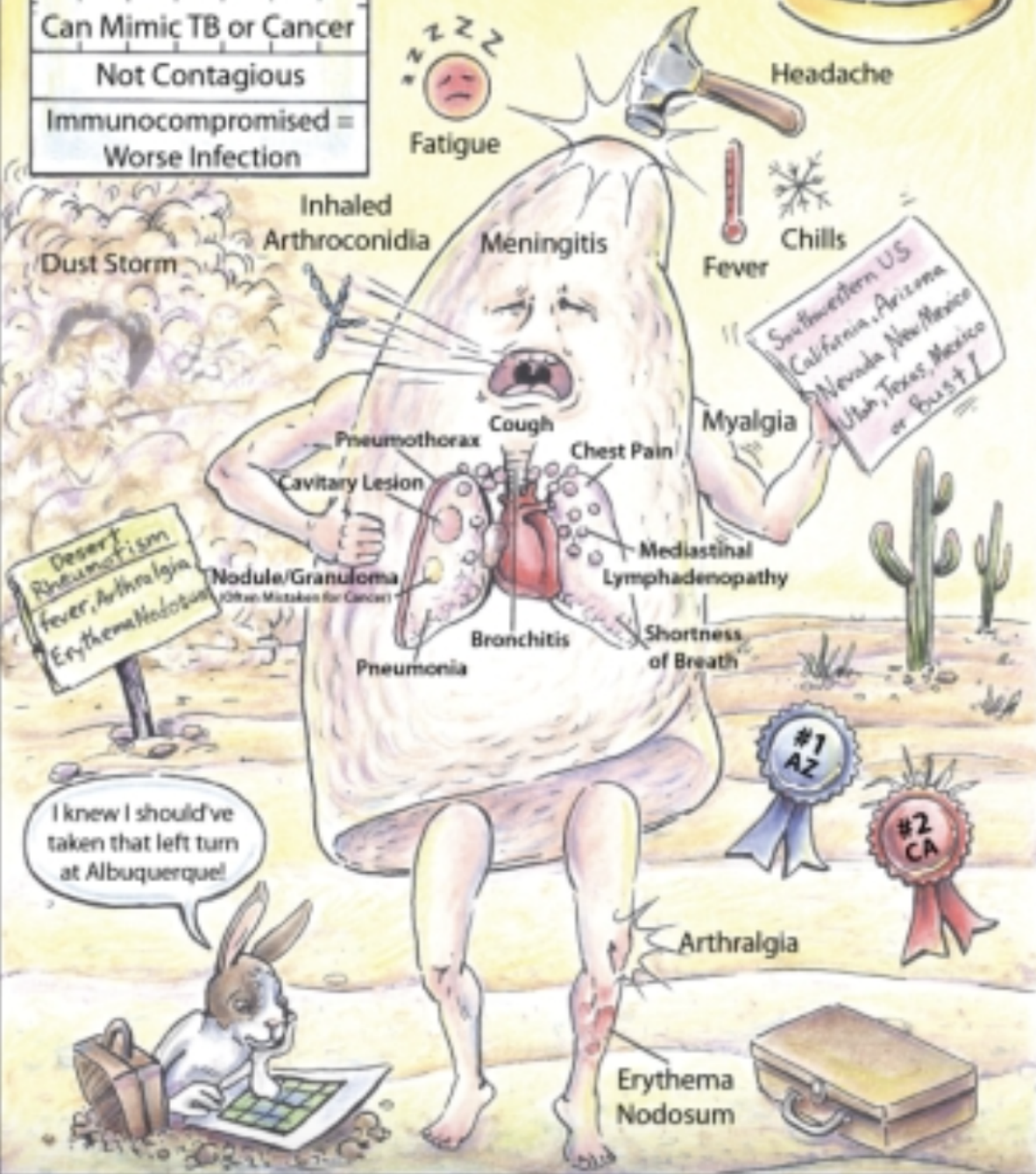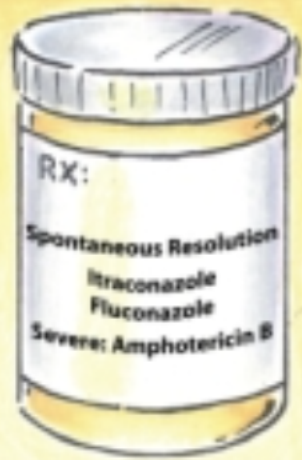
Coccidioides immitis
Coccidioides posadasii

(San Joaquin Valley Fever)

S	M	T	W	T	F	S
Incubation: 7-21 Days						
≈ 50% Asymptomatic or Mild						
5% Chronic Infection						
Can Mimic TB or Cancer						
Not Contagious						
Immunocompromised = Worse Infection						



Dimorphic Fungi

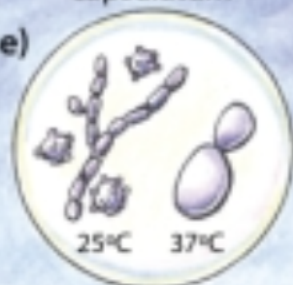


Histoplasmosis

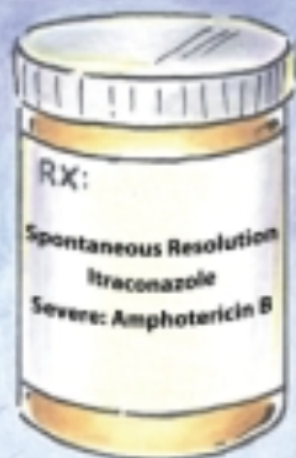
(Spelunker's Lung/Cave Disease)

S	M	T	W	T	F	S
Incubation: 3-17 Days						
~90% Asymptomatic or Mild Infection						
Can Mimic TB						
Not Contagious						
Immunocompromised = Worse Infection						


Histoplasma capsulatum



Dimorphic Fungi



Fatigue



Headache



Chills

Meningitis

Inhaled Conidia

Cavitary Lesion

Cough

Substernal Chest Pain

Mediastinitis

Mediastinal Lymphadenopathy

Nodule/Granuloma
(Often Mistaken for Cancer)

Pericarditis
~ 5%

Patchy Pneumonitis

Yo, I'm trying to sleep bro!

Hepatosplenomegaly

Erythema Nodosum

Black Birds
Starlings



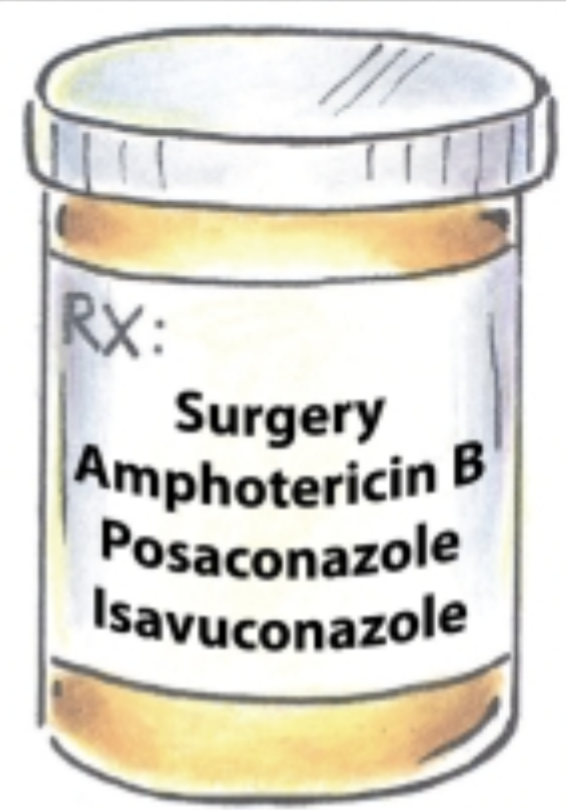
Arthralgia



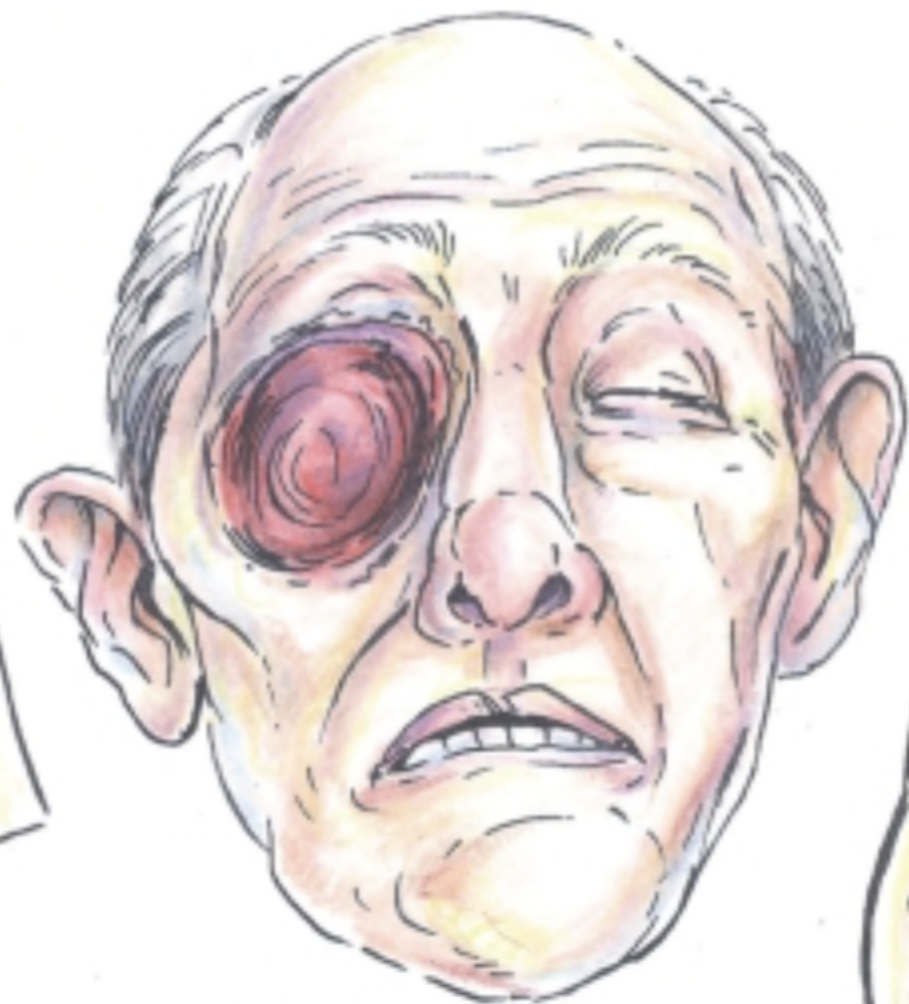
Guano

Mucormycosis

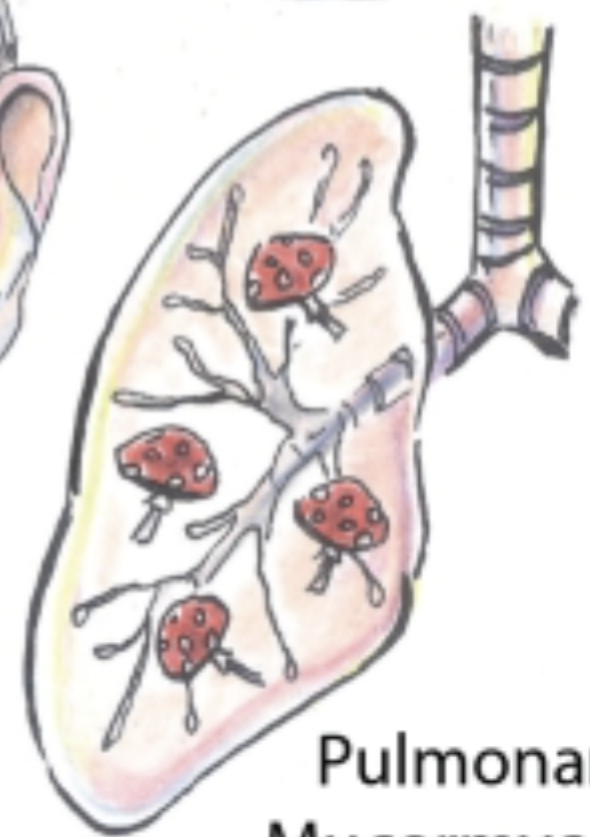(Zygomycosis)



- Risk Factors
- Diabetes
 - DKA
 - Immunocompromised
 - Hematologic Malignancy
 - Transplant Recipients
 - Deferoxamine Therapy



Rhinocerebral
Mucormycosis



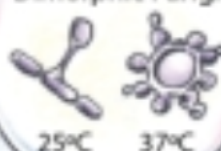
Pulmonary
Mucormycosis

Paracoccidioidomycosis

(South American Blastomycosis)

Paracoccidioides
brasiliensis

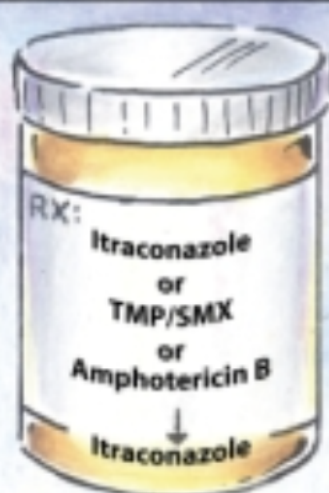
Dimorphic Fungi



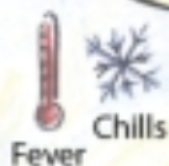25°C

37°C

Paracoccidioides
lutzii



S	M	T	W	T	F	S
Incubation: 1 month—9 Years						
≈5%—10%: Acute/Subacute or "Juvenile" = Rapid						
≈90%: Chronic or "Adult" = Insidious						



Fever

Chills

Mucocutaneous
Lesions

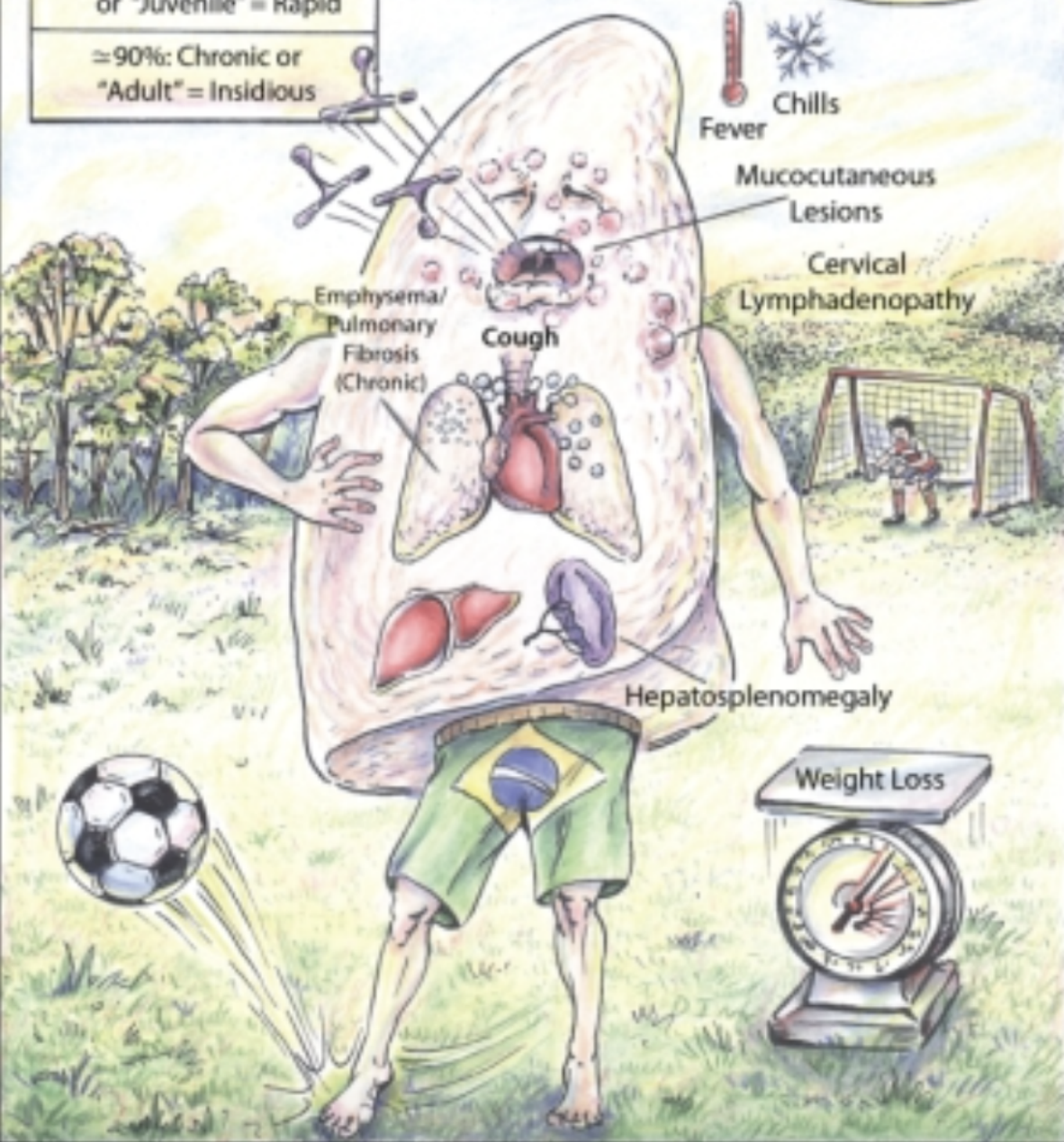
Cervical
Lymphadenopathy

Emphysema/
Pulmonary
Fibrosis
(Chronic)

Cough

Hepatosplenomegaly

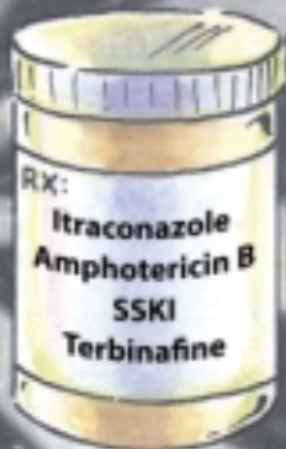
Weight Loss



Sporotrichosis

(Rose Gardener's Disease)

S	M	T	W	T	F	S
Incubation: 1-12 Weeks						
Average: ~3 Weeks						



Sporotrichosis Meningitis
(Disseminated)

Lymphocutaneous

"Every Thorn has its Sporothrix"

Pulmonary
(Spore Inhalation = Rare)

Cutaneous

I can catch
and spread
the infection!

Osteoarticular
(Disseminated)



Daisy Wheel



Cigar Body



Mold

Yeast



Roses and Plants



Hay

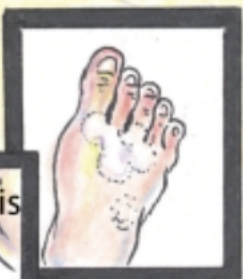

Soil

The AMAZING TINEA ON MAN



Tinea Pedis



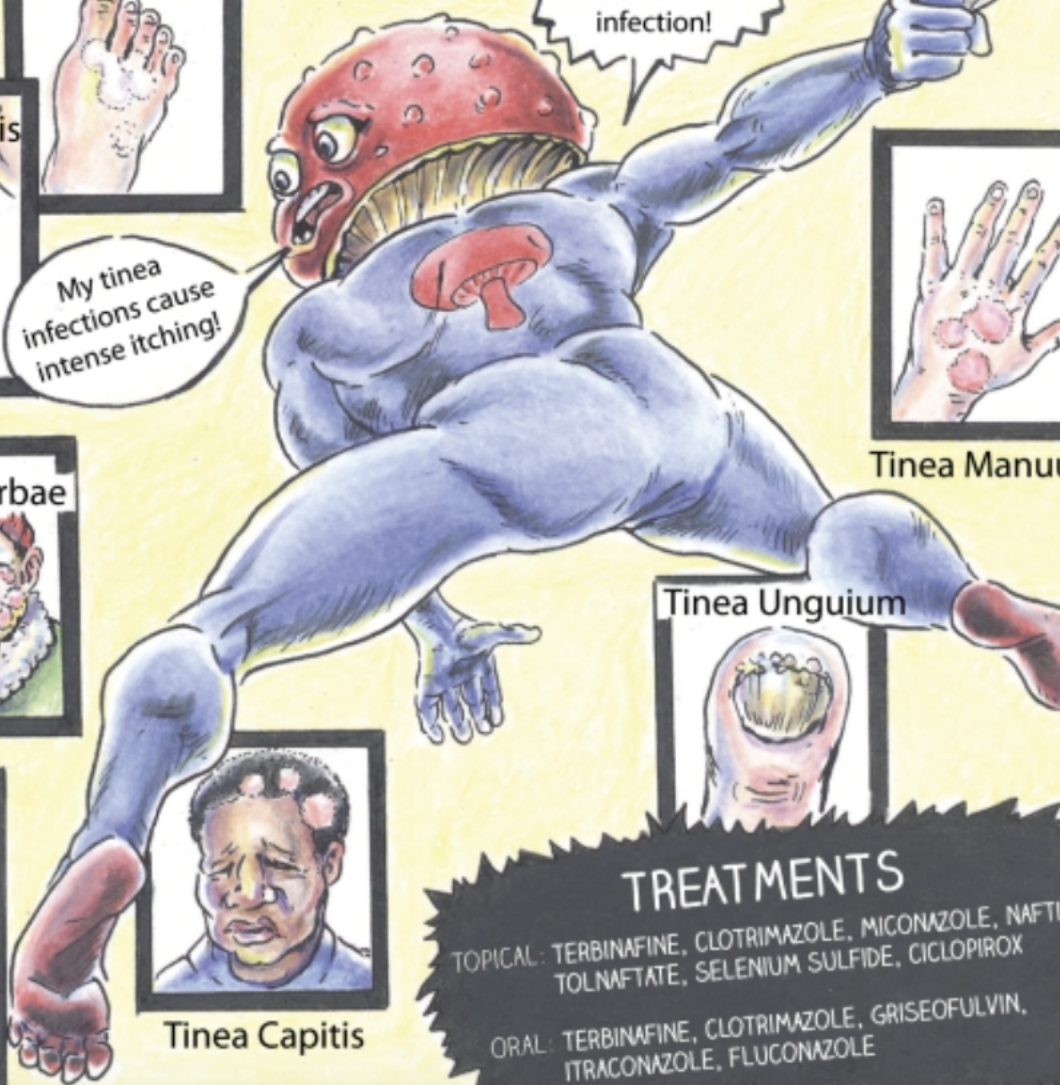
Corporis



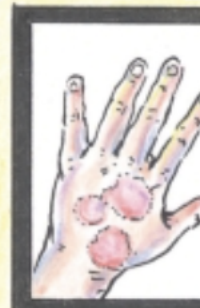My tinea infections cause intense itching!

Somewhere I'll cause a local infection!

But where?



Tinea Manu



Tinea Barbae



Tinea Unguium



Tinea Cruris



Tinea Capitis



TREATMENTS

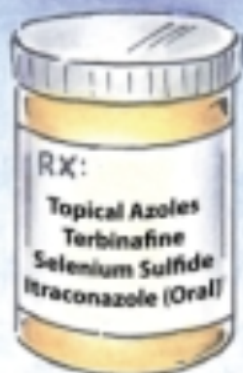
TOPICAL: TERBINAFINE, CLOTRIMAZOLE, MICONAZOLE, NAFTOLNAFTATE, SELENIUM SULFIDE, CICLOPIROX

ORAL: TERBINAFINE, CLOTRIMAZOLE, GRISEOFULVIN, ITRACONAZOLE, FLUCONAZOLE

Tinea Versicolor

(Pityriasis Versicolor)

Malassezia globosa
Malassezia furfur



More Common
in the Tropics

So listen, I'm a doctor and you've got a fungus growing in your back. It can be hyper- or hypopigmented and gets more pronounced with sun exposure. I can recommend a topical cream for you...

Affects trunk and
proximal limbs.

Fluoresces yellow-green
under Wood's lamp.

